

### III. *Description of the Brain of Mr. Charles Babbage, F.R.S*

(*Hunterian Museum, Royal College of Surgeons.*)

By Sir VICTOR HORSLEY, *F.R.S., F.R.C.S.*

(Received December 14, 1907,—Read March 12, 1908.)

[PLATES 9–13.]

THE brain of the distinguished mathematician, Mr. CHARLES BABBAGE, was under special instruction removed by Sir THOMAS SMITH and placed in the care of the Hunterian Trustees, at whose request the following report on the specimen has been prepared.

The whole brain is small, shrunk by prolonged immersion (36 years) in alcohol, which renders the outlines of the sulci difficult to photograph, but it has been beautifully preserved in the Hunterian Museum. Its examination was greatly facilitated by the kind assistance and advice of the late Professor CHARLES STEWART, F.R.S., Curator of the Hunterian Museum, Royal College of Surgeons of England.

Adopting the principles laid down by Professor G. RETZIUS (see No. 6), the present account will consist in a systematic description of the sulci and gyri, with but a few remarks on any apparent correlation between the cerebral morphology and Mr. BABBAGE'S psychical characteristics.

At the same time, attention may properly be here drawn to the fact that the important neurological method of collecting systematic records of the brains of distinguished men, which was commenced in this country by the late Mr. JOHN MARSHALL, F.R.S., requires the support of the learned Societies for its adequate execution. Until such organised and combined action has resulted in the collection of a large number of facts, it is impossible to make deductions of scientific value on the relation between special mental characteristics and cerebral development.

#### BIOGRAPHICAL NOTICE.\*


CHARLES BABBAGE was born on December 26, 1791, and died on October 18, 1871. His family had been settled in Devonshire for several centuries, but his

\* Many of the facts of Mr. BABBAGE'S life, as well as a list of his scientific papers, are stated in his autobiographical memoir, entitled 'Passages from the Life of a Philosopher,' 1864. I am also greatly indebted to Dr. DUDLEY BUXTON (whose father, Mr. WILMOT BUXTON, an intimate friend and close companion of Mr. BABBAGE, wrote a manuscript life of the mathematician), for the opportunity of reading this "Life" and for his own personal recollections. Similarly, Sir THOMAS SMITH, Bart., has kindly informed me from his personal knowledge on many important points, and has substantiated the accuracy of the available records of Mr. BABBAGE'S life.

(264.)

21.7.08.

own branch almost became extinct at his death, for he states that in 1864 no collateral relative of his name belonging to the four previous generations was then alive. He entered Trinity College, Cambridge, moving later to Peterhouse, and took his degree at 22 years of age, acquiring a high reputation as a mathematician. Two years later he was made a Fellow of the Royal Society, having already accomplished noteworthy research in mathematics. His earlier work, viz., the examination of the systems of notation of NEWTON and LEIBNIZ, led him, even before his graduation, to formulate his first conceptions of computing by machinery.



To the accomplishment of this object he devoted the major part of his life and private fortune, and, with some financial assistance from the Government, began the construction of an engine for the calculation of tables by the method of differences.

Unfortunately, only a small portion of this machine was completed and actually employed in a Government department, when he became involved in complex mathematical speculations for the design and construction of an analytical engine.

As a natural consequence, little was completed or finally accomplished of either machine. The method, nevertheless, was successfully adopted in Sweden.

There is no doubt that Mr. BABBAGE was a very profound thinker, that his mentation carried with it complete fixation of attention (often to the exclusion of

dōmestic duties), and that he was able to resolve complex conditions by an unusual power of forming wide concepts.

His rapidity of formation of percepts was considerable, and led him to engage in a very extensive range of subjects beyond those which (*e.g.*, insurance, taxation, etc.) appropriately admitted of treatment by mathematical methods. His special senses were very active. His appreciation of both colour and music was highly cultivated.

As regards the efferent side of the function of the cortex cerebri, he was right-handed and a skilled worker with tools. His speech function was highly developed, both on its afferent and efferent sides.

At the date of his death he was a Member of all the principal Scientific Societies in the United Kingdom, and was an Honorary or Corresponding Member of the leading European Academies and Imperial Institutes of Science.

He died, aged 80 years, of renal inadequacy, secondary to cystitis.

As will be seen on reference to the plates, the brain exhibits no sign of senile wasting of gyri nor patches of softening from atheroma. (The blood vessels and membranes have all been removed.) At the same time it is to be remembered that the whole organ has uniformly shrunk and has lost about one-third of its weight; thus any moderate atrophic widening of the sulci may have been obliterated.

#### THE LEFT CEREBRAL HEMISPHERE. (Plates 9–11 and 13.)

##### Lobus frontalis.

This is remarkably well and regularly developed,—thus in it the typical three horizontal frontal sulci can be readily differentiated and described.

*Sulcus præcentralis superior.*—Short, directed almost parallel to the mesial plane. Opposite the junction of its middle and posterior thirds is a deep sulcus inflectalis.

*Sulcus frontalis superior.*—Begins (posteriorly) 3·5 cm. from the mesial plane and just in front of the upper end of the sulcus præcentralis inferior, from which it is separated by a narrow (4 mm.) gyrus connecting the superior and middle frontal gyri.

The sulcus is completely divided into three portions by annectent gyri which are completely exposed on the surface. The first of these is midway between the posterior end of the sulcus and the frontal pole of the hemisphere.

The second bridging gyrus is double by reason of the development of a secondary sulcus at right angles to the margin of the hemisphere.

The relation of the end of the sulcus frontalis superior to the frontal pole is given below in special detail; it approaches the margin of the hemisphere until it is separated from the mesial plane by a gyrus only 12 to 14 mm. broad.

*Sulcus frontalis medius.*—Begins by a wide T-shaped origin one-third of the distance between the sulcus præcentralis inferior and the frontal pole. It is uninterrupted throughout and ends by a wide-angled bifurcation above the pole.

*Sulcus frontalis inferior.*—Begins by a deep notch in the anterior wall of the sulcus

præcentralis inferior, bridged at bottom by a narrow (3 mm.) gyrus. In front the sulcus ends close to the anterior extremity of the sulcus medius. A stellate secondary sulcus occupies the broadened end of the third frontal gyrus.

*Sulcus præcentralis inferior.*—Commences below by a deep (bridged, of course) notch in the opercular margin and ends opposite the hinder end of the sulcus frontalis superior.

Its anterior, or horizontal, limb, ramus horizontalis, is short and scarcely exceeds more than the breadth of the gyrus frontalis medialis it invades.

*Sulcus diagonalis.*—This sulcus is deep and joins with the ramus anterior of the Sylvian fissure in cutting the opercular margin.

*Sulcus subcentralis anterior.*—This is a powerfully developed sulcus vertically dividing the lower third of the gyrus centralis anterior, slightly notching the anterior margin of the sulcus centralis Rolandi.

*Sulcus centralis Rolandi.*—The fissure\* of Rolando of the left hemisphere is a boldly drawn sulcus with a very sharply defined *genu inferior*, the portion of the sulcus below this being directed so far backwards as to make anteriorly an angle of  $82^\circ$  with the *sulcus Sylvii*.

Consequently the direction of the whole left fissure as located by its extremities is a line almost exactly at right angles to the mesial plane, viz.  $88^\circ$ .

When the direction of the line forming the extremities of the sulcus is taken as representing that of the sulcus as a whole, this constitutes one of the most brachycephalic central sulci I have seen. The angle which the line of direction from the upper end of the sulcus to the inferior genu makes with the mesial plane is  $70^\circ$ . The remarkable development of the lower end of the gyrus frontalis ascendens causes this condition of the sulcus centralis.

The gyrus centralis anterior thus outlined by the sulci described is particularly massive, broad and simple in outline, contrasting notably with that of the right hemisphere, *vide infra*, p. 125.

*Sulcus inflectalis.*—In this, the left hemisphere, the sulcus is a deep incisure of the margin, making an angle anteriorly with the mesial plane of  $50^\circ$  and almost reaching the sulcus præcentralis superior.

#### Lobus parietalis.

*Sulcus parietalis superior.*—This sulcus, by reason of a complete bridging gyrus, is entirely separate from the sulcus intraparietalis. It begins horizontally behind the genu inferior of the Rolandic fissure, courses upwards parallel to the latter and just stops short of notching the margin of the hemisphere.

*Sulcus interparietalis.*—In accord with the general complexity of the occipito-temporal region the interparietal sulcus extends from the posterior border of the

\* Throughout this paper the fissures and sulci will not be arbitrarily divided, but will be all referred to as "sulci."

gyrus centralis posterior to the anterior border of the gyrus occipitalis primus vel medialis, *i.e.*, to the gyrus separating it from the posterior limit of the calcarine sulcus. Superficially, therefore, it corresponds to just half the total length of the hemisphere. It takes the usual course, *i.e.*, mesialwards, until just before reaching the sulcus parieto-occipitalis (pars externus), when it runs parallel to the sagittal plane until opposite the (transverse) plane of the centre of the horizontal limb of the sulcus calcarinus, when it turns downwards.

Owing to the fact that all its parts, *i.e.*, sulcus postcentralis inferior, ramus horizontalis and ramus occipitalis, are all confluent, there is no definite *sulcus transversus* present, and the sulcus is not bridged at any point, at least by any gyrus reaching up to 10 mm. of the surface.

*Ramus mesialis*.—This is present as a short sulcus terminating by a T-shaped end on the margin.

*Sulcus retrocentralis superior*.—This subordinate sulcus subdivides the parietal lobule into an anterior and posterior half.

*Sulcus parieto-occipitalis*. (a) *Pars externus*.—The external portion of this important fissure is a short deep sulcus, cutting the margin of the hemisphere very deeply at an angle of  $72^\circ$  with the mesial plane.

(b) *Pars internus*.—The inner portion is a deep vertical cleft (*incisura parieto-occipitalis*) of the mesial face of the hemisphere which joins below with the calcarine fissure. On separating its lips, the usual tri-radiate secondary sulcus is seen on the anterior wall.

*Sulcus retrocentralis inferior*.—This is a tri-radiate sulcus subdividing the inferior parietal lobule. Its posterior extremity coincides with the posterior end of the fissure of Sylvius by reason of an early fusion of the superior temporal and supra-marginal gyri.

*Sulcus subcentralis posterior*.—This is present as a short unbranched sulcus, cutting the upper margin of the Sylvian fissure.

*Sulcus Sylvii*.—In general the fissure of Sylvius does not at first sight appear abnormal, but, as a matter of fact, it is notably shortened posteriorly by the annectation just mentioned.

(a) *Ramus horizontalis anterior*.—This arises by a common stem with the ramus ascendens, and is a short cleft separating the frontal operculum from the orbital lobe.

(b) *Ramus anterior ascendens*.—This, the formerly termed anterior limb of the fissure, is also short, and runs vertically upwards, parallel to and only 8 mm. separated from the sulcus præcentralis inferior.

(c) *Ramus posterior ascendens et descendens*.—This important part of the fissure barely occupies 40 (39·3) per cent. of the total length of the hemisphere owing to the degree of gyrus development of the inferior parietal and occipito-temporal region.

On separating its lips the relations of the insula are seen to be normal, as follows :

#### **Lobus insularis (REILII).**

*Sulcus circularis vel limitans insulæ.* (a) *Pars fronto-parietalis.*—This part of the sulcus is deep, and is not joined by the secondary sulci of the insula (*vide infra*).

(b) *Pars frontalis.*—The frontal part of the sulcus bordering the insula lies at the bottom of the stem of the sulcus Sylvii, and is itself short but deep.

(c) *Pars temporalis.*—The temporal part of the circular sulcus presents the normal gradual widening anteriorly with the sharp bend inwards.

The sulci separating the gyri Andreae Retzii nowhere cut into the sulcus circularis.

*Sulci insulares (REILII).* (a) *Sulcus centralis insulæ (GULDBERG).*—This is a well-marked sulcus dividing the insula into an anterior three-fifths, *lobulus insulæ anterior vel frontalis*, and a posterior two-fifths, *lobulus insulæ posterior vel parietalis*.

Its direction is but a few degrees ( $12^\circ$ ) divergent from that of the ramus horizontalis posterior of the sulcus Sylvii, and, consequently, its principal axis, viewed from above, makes an angle anteriorly with the mesial plane of approximately  $57^\circ$ .

(b) *Sulci anteriores insulæ.*—The triangular mass of cortex in front of the sulcus centralis insulæ is divided into three equal parts by two sulci, which run at right angles to the mesial plane and are shallow.

(c) *Sulcus posterior.*—The *lobulus posterior* of the insula is divided into two gyri by a deep sulcus (sulcus posterior insulæ), which runs parallel to the sulcus centralis. It ends dorsally and ventrally short of the sulcus circularis vel limitans.

(For comparison of the two insulæ, see p. 126.)

#### **Lobus temporalis.**

This lobe is on the left side, notably subdivided at the anterior confluence of the temporal gyri. As the brain has considerably flattened in the alcohol, it is not possible to estimate the relative depth of the lobe, but it is complexly and well developed.

*Sulci transversi (RETZIUS).*—On the upper (Sylvian) aspect of the left temporal lobe are three sulci transversi posteriorly to the angle of the sulcus circularis vel limitans, *q.v.* In front of this angle, *i.e.*, concentric with the sulcus circularis and the polar margin of the lobe, is a deep sulcus semicircularis. (This sulcus is also described under the name sulcus transversus anterior.)

*Sulcus temporalis superior (parallel sulcus).*—This sulcus has a long course posteriorly extending at right angles to the mesial plane to 1.5 cm. distance from the sulcus intraparietalis.

Anteriorly it is stopped in the vertical plane of the lower end of the sulcus præcentralis inferior by a powerful bridging gyrus on the surface of which is a subordinate sulcus. Beyond this bridging gyrus there is a large sulcus semicircularis coursing parallel to the polar and upper margin of the lobe.

*Sulcus temporalis inferior.*—This sulcus begins posteriorly in the same vertical plane as the ramus horizontalis of the fissure of Sylvius, and ends in a deeply-cut T-shaped extremity, which lies transversely to the long axis of the lobe.

*Sulcus temporalis medius.*—This sulcus cuts the temporal margin of the hemisphere very deeply, and extends equally on the outer and lower surfaces of the lobe. Thus above it marks off a very wide posterior limb of the gyrus angularis, and approaches superficially to within 1·3 cm. of the sulcus intraparietalis (ramus occipitalis). Tentorially it runs towards the sulcus ectorhinalis, from which it is separated by the hook-like continuation of the *sulcus collateralis*.

*Sulcus collateralis.*—This is widely spread, by reason of the great tentorial breadth of the lobe. The sulcus begins posteriorly by a wide T-shaped sulcus extending along the whole margin of the gyrus occipitalis inferior. From the centre of this sulcus, which might be termed (for this brain) the sulcus occipitalis lateralis vel tentorialis, the collateral sulcus runs forwards, receives a large branch subdividing the gyrus lingualis, then borders the limbic lobe, and turns round to form its hook-like portion in the transverse plane of the interpeduncular space.

#### Lobus occipitalis.

The tip of the left occipital lobe has unfortunately been lacerated, but the arrangement of the sulci is easy to discern.

There are two lateral sulci distinguishable, as well as one paramedian, in addition to which the ramus occipitalis of the intraparietal sulcus cuts very deeply and extensively into the lobe, reaching superficially close to the polar margin.

*Sulcus paramesialis.*—This is a subordinate sulcus, cutting the margin of the hemisphere into the lobus cuneus, and externally to the middle of the gyrus occipitalis superior.

*Sulcus intrastriatus lateralis (vel sulcus occipitalis superior).*—This, which is absolutely a subordinate sulcus, nevertheless cuts deeply the lower half of the gyrus occipitalis superior, and extending posteriorly, is only separated from the centre of the T-shaped extremity of the sulcus calcarinus by a narrow gyrus 0·3 centim. wide.

*Sulcus lunatus.*—This sulcus, though also subordinate in size, is the sulcus lunatus occipitalis of ELLIOT SMITH. Superficially it appears to be the T-shaped end of the ramus occipitalis of the sulcus intraparietalis, but it is separated therefrom by a gyrus.

*Sulcus calcarinus.* (a) *Ramus posterior* (sulcus intrastriatus mesialis (retro-calcarinus)).—The posterior limb of the sulcus is nearly subdivided by the gyrus cuneo-lingualis posterior becoming superficial. The lower lip is increased by a subordinate sulcus dividing the gyrus lingualis deeply.

(b) *Ramus anterior* (vel sulcus calcarinus proprius).—This limb simply divides the gyrus lingualis from the lobus limbicus.

#### Superficies mesialis.

*Sulcus cinguli* (vel calloso-marginalis).—This sulcus, which follows the usual

course, begins (owing to high development of the frontal lobe) in the vertical plane of the hindermost limit of the rostrum, which is sharper and more recurved than usual. It is uninterrupted throughout. Concentric with it are numerous parallel subordinate sulci, subdividing not only the gyrus marginalis but also the lobus limbicus. It terminates posteriorly in a very marked *incisura cinguli*.

*Sulcus rostralis*.—As in the opposite hemisphere, the rostral sulci, both primary and secondary, are extremely well developed and subdivide the median aspect of the fronto-orbital lobe so as to emphasise the generally high type of development of this region.

*Polus frontalis*.—The frontal pole of the left hemisphere is interesting by reason of the subdivision of the gyri and their annectent developments. Part of it, namely the orbital margin, is cut by a concentric sulcus lying parallel to the T-shaped end of the sulcus frontalis medius, namely the *sulcus fronto-marginalis*.

*Lobus orbitalis*.—In accord with the general convolitional complex arrangement of this brain the lobus orbitalis, as the orbital portion of the frontal lobe may justly be termed, is subdivided by five sulci, all of which are present in the specimen, viz. :—

Sulcus orbitalis transversus anterior,  
Sulcus orbitalis transversus posterior,  
Sulcus orbitalis internus,  
Sulcus orbitalis externus,  
Sulcus olfactorius,

but which do not require detailed description.

*Lobus limbicus*.—The limbic lobe presents a simple appearance. The rhinencephalon is narrow and rather flattened. It presents a sharply marked olfactory tubercle.

*Lobus parietalis. Præcuneus* (Lobulus quadratus).—The quadrate lobule or præcuneus is well marked and its surface notably subdivided.

*Sulcus subparietalis*.—The præcuneus exhibits above a well-marked sulcus subparietalis.

*Sulci præcunei*.—The rest of the lobe presents two vertical sulci præcunei.

#### RIGHT CEREBRAL HEMISPHERE. (Plates 9, 11, 12, and 13.)

The right cerebral hemisphere is very richly convoluted, especially in the development of the frontal and occipito-temporal regions.

##### Lobus frontalis.

*Sulcus frontalis superior*.—This sulcus begins posteriorly in apparent fusion with the ramus verticalis of the sulcus præcentralis superior, from which it is really separated by a buried gyrus. It runs forwards parallel to the mesial plane until the junction of the anterior and middle thirds of the lobe, when it turns inwards and ends 1 cm. from the mesial surface.

Here it is completely interrupted by a double bridging gyrus, as on the left side, but more fully developed by reason of a deeply invading transverse marginal sulcus,



which by branching on the external surface causes such width of cortical folding as to abolish all further continuation of the line of the sulcus frontalis superior.

*Sulci paramesiales.*—Between the sulcus and the mesial plane are three sulci paramesiales.

*Sulcus frontalis medius.*—The commencement of this sulcus is posteriorly subdivided by a narrow gyrus, so that a subordinate but deep sulcus which breaks up the posterior third of the gyrus frontalis secundus (medius, pars superior) is really the line of origin of the whole sulcus.

The sulcus frontalis medius courses forwards and inwards and terminates at the frontal pole, the outer half of its T-shaped end being practically absent. Consequently, the medial half apparently prolongs the sulcus to 0·5 cm. from the mesial plane.

*Sulcus frontalis inferior.*—A fusion similar to that of the sulcus præcentralis superior occurs between the sulcus præcentralis inferior and the sulcus frontalis inferior. This latter is a simple horizontal sulcus terminating at the orbital margin, where it is arrested by a very narrow gyrus dividing it from the sulcus diagonalis.

*Polus frontalis.*—In the right hemisphere the frontal pole is rather simpler than on the left side, there being no thoroughly marked concentric horizontal sulcus behind the orbital margin, but there is a lateral subdivision of the sulcus orbitalis internus which affords the parallel to the left side.

*Sulcus orbitalis.*—This sulcus presents the characteristic H-figure, and both the parts, namely, the sulcus orbitalis externus and internus, are long and branching.

*Sulcus olfactorius.*—This is a simple groove.

*Sulcus marginalis.*—This sulcus is remarkably symmetrical with its homologue of the opposite side. The direction of its two extremities joined makes an angle of about 40° with the mesial plane. The two sulci together make an angle anteriorly of exactly 90°. The sulcus cuts the gyrus marginalis very deeply.

*Sulcus præcentralis superior.*—This sulcus is exceptionally developed. Its ramus verticalis extends over 50 per cent. of the breadth of the lobe. Its ramus horizontalis is very short and parallel to the commencement of the sulcus frontalis superior, *q.v.*

*Sulcus præcentralis inferior.*—This sulcus, although vertically presenting a usual arrangement and symmetrical with that of the left side, occupies at its lower extremity the site of the sulcus subcentralis anterior, which, therefore, is represented by such part of the sulcus præcentralis. In front of this lies a true sulcus diagonalis. The lower end of the gyrus centralis anterior is only slightly dimpled.

*Sulcus diagonalis.*—In this, the right hemisphere, the sulcus diagonalis is a strongly-marked independent sulcus. It notches the edge of the operculum superficially.

*Sulcus centralis.*—The Rolandic sulcus of the right hemisphere is not divided so remarkably by change of direction of its two parts as in the left hemisphere. Thus, the line joining its two ends makes an angle of 76° with the mesial plane. This

difference is owing to the fact that the genua are not so sharply marked, and the direction of the inferior half of the sulcus is vertical and not backwards as on the left side. The gyrus centralis anterior (ascending frontal) is, consequently, much narrower than on the left side.

*Sulcus Sylvii*.—This important fissure is remarkably symmetrical with that of the left hemisphere. It extends by its ramus posterior somewhat further posteriorly, *i.e.*, to the normal central plane of the gyrus supra-marginalis, but otherwise requires no special description.

#### Lobus insularis (REILII).

*Sulcus limitans insulae Reilii*.—This sulcus, though shallower, has the same typical arrangement as in the left hemisphere, and it is not cut into by any of the neighbouring sulci, whether insular or opercular.

*Sulcus centralis insulae*.—This deep sulcus runs at an angle anteriorly of about  $15^\circ$  with the ramus posterior of the Sylvian fissure. It divides the insula precisely as on the left side, and similarly the pars frontalis and parietalis insulae are subdivided by three shallow sulci and one deep sulcus respectively.

The right insula is less developed than the left, and the gyri are flatter and simpler. This is in accord with the general observations of WALDSCHMIDT (see No. 10), especially as Mr. BABBAGE was right-handed.

#### Lobus parietalis.

The complexity of the subdivision of the occipito-temporal and lower parietal region, which was notable in the left hemisphere, is also present to a marked degree in the right. This anatomical evidence of the high status of this brain is in harmony with the view of CUNNINGHAM and others (see No. 1).

*Sulcus post-centralis inferior* vel *Sulcus parietalis transversus*.—This very deep sulcus subdivides the foot of the gyrus centralis posterior so as to leave but a small portion of cortex in front and above. It is shortened by the fact that the sulcus intraparietalis begins low down.

*Sulcus post-centralis superior* is an irregular and obliquely placed sulcus, its general direction making an angle of  $60^\circ$  with the upper third of the sulcus centralis. Hence, it marks off a broad piece of the gyrus parietalis.

*Sulcus interparietalis*.—This sulcus begins by a large and deep H-shaped origin, and follows a course quite similar to that of the left side, but ends by a T-shaped extremity just behind the sulcus parieto-occipitalis, owing to the development of a large occipito-angular annectent gyrus.

The lobulus parietalis superior is simply subdivided by a subordinate sulcus. A vertically directed branch of the sulcus interparietalis takes the place of the ordinary posterior upcurved extremity of the ramus horizontalis posterior of the sulcus Sylvii.

A small subordinate shallow sulcus subdivides the centre of the gyrus supra-marginalis,

**Lobus temporalis.**

The right temporal lobe, like the left, is highly developed, as also is the associated occipito-temporal region.

*Sulcus temporalis superior* (parallel sulcus).—The parallel sulcus commences close (3 mm.) to the sulcus interparietalis and runs down parallel to the fissure of Sylvius, terminating opposite the vertical plane of the sulcus præcentralis inferior.

*Sulcus temporalis inferior*.—This is a very long sulcus, beginning above with the parallel sulcus and, though interrupted in the middle, its direction is continued until it terminates by an **H**-shaped end, the mesial half of which reaches almost the rhinal pole of the lobe.

The central interruption of the sulcus is double by reason of the development of a broad (2·5 cm.) gyrus which unites the gyri temporales medius et inferior and is itself subdivided by a secondary sulcus.

*Sulcus temporalis concentricus*.—Two subordinate concentric sulci follow the margin of the pole of the lobe on its outer surface.

*Sulcus occipito-temporalis* vel sulcus temporalis inferior (RETZIUS and other authors).—As in the left hemisphere, the sulcus occipito-temporalis very deeply cuts the tentorial margin, forming a well-marked *incisura præoccipitalis*, at the bottom of which are interlocking gyri and a subordinate sulcus on the posterior wall of the cleft.

*Sulcus collateralis*.—The right collateral sulcus is symmetrical with that of the left side. The inferior or tentorial surface of the lobe is equally divided by the sulcus which, as on the opposite side, begins in a well-marked **T**-shaped end, constituting a concentric sulcus. The actual junction of the two sulci is bridged closely below the surface by a narrow gyrus.

*Sulcus hippocampi*.—This important sulcus is perfectly simple in outline.

**Lobus occipitalis.**

The right lobus occipitalis is much subdivided, and the pole presents a deep lateral sinus groove (BASTIAN).

*Sulcus calcarinus*.—The general plan of the sulcus calcarinus is exactly that of the left hemisphere, but simpler. In its depth are well-defined anterior and posterior cuneolingual gyri.

*Sulcus limitans areæ striatæ superior*.—This important topographical sulcus is extremely well marked.

*Sulcus cunei*.—The cuneus is divided deeply by a well-marked secondary sulcus which cuts the margin of the hemisphere.

*Sulcus occipitalis intrastriatæ lateralis superior*.—The sulcus lateralis superior is very well marked and is not invaded by the sulcus intraparietalis.

*Sulcus occipitalis lunatus* vel *lateralis inferior*.—Parallel to the sulcus lateralis inferior is an inferior one, much shallower, but furnished with secondary branches.

*Sulcus parieto-occipitalis*. (a) *Pars externus*.—The external part of this sulcus is

very short, extending not more than 1.4 cm. from the mesial surface. It is very deep and contains the upper end of the anterior wall subordinate sulcus.

(b) *Pars internus v. mesialis*. This part, like that of the left side, is very deep and presents a subordinate sulcus on both the anterior and posterior walls.

#### Superficies mesialis.

*Sulcus subparietalis*.—This is a well-marked H-shaped sulcus subdividing the lobulus quadratus symmetrically.

*Sulcus cinguli* (v. *Sulcus calloso-marginalis*).—This, with the other sulci of the mesial surface, is remarkably developed and symmetrical with that of the other side. It is uninterrupted from its origin posteriorly, where it deeply cuts the margin of the hemisphere, until it ends in front at the posterior extremity of the gyrus rectus frontalis.

*Sulcus rostralis*.—Parallel to the sulcus cinguli is a very deep and richly branched sulcus rostralis. It begins first in front of the central plane of the lobus frontalis and superficially ends (not actually) in the anterior extremity of the sulcus cinguli. By its branches it repeatedly divides the marginal gyrus, which is also indented by paramedial shallow subordinate sulci.

One such, deeper than the rest, may be recognised as the sulcus rostralis inferior.

#### The Gyri.

The condition of relative development of the gyri is better revealed by inspection of the photographs than any description in words. This, however, is the place in which a comparison of the special areas in the two hemispheres should be given. As will have been recognised from the description of the sulci, there is a very marked symmetry of the lobes and their subdivisions.

*Lobus limbicus*.—The gyri cinguli are perfectly similar, the gyri rostrales are as nearly absolutely symmetrical as possible, and the same is true of the gyri semilunares Retzii and the tubercula olfactoria.

*Lobus frontalis. Pars orbitalis*.—The orbital gyri, apart from complexity, offer nothing for special mention.

*Pars externus*.—The gyri of the pole and of the regio præfrontalis\* are much subdivided and complex in both hemispheres.

The posterior third of the gyrus frontalis superior is simple on both sides, but the right is rather more complex than the left.

The *gyrus centralis anterior* is strikingly different in the two hemispheres, that of the left being very notably more massive and developed than that of the right side.

Thus the breadth of the right gyrus just above the genu inferior, *i.e.*, the lower part of the area for the upper limb representation, is 1.2 cm., whereas the left is 1.6 cm. Further, the breadth of the lower end of the right gyrus at a point 1.5 cm. above the

\* *I.e.*, the region in front of the plane of the sulcus præcentralis inferior.

sulcus Sylvii is 1.3 cm., whereas the left gyrus at the same height is 2.75 cm., *i.e.*, more than twice in volume.

Hence, a very extensive area of cortex for the representation of the movements of the larynx, tongue, and jaw is provided in the left hemisphere.

The *lobuli paracentrales* are symmetrical and simple.

*Lobi occipitales*.—The gyri of the occipital lobes are both alike in complexity and arrangement.

*Lobi temporales*.—The gyri of the rhinal poles of the temporal lobes are distinctly more complex in the left than right hemisphere, but their arrangement is alike.

The *gyrus temporalis superior* is larger in the left hemisphere and the whole outer surface of the lobe appears larger, the gyri more bridged and folded, than on the right hemisphere.

*Regio occipito-temporalis*.—The *incisura præoccipitalis* is exceedingly well marked on both sides, and is not bridged in either hemisphere. The mass of gyri in front of it, *i.e.*, the region including the posterior thirds of the temporal gyri, the anterior limb of the gyrus angularis, and the gyrus supramarginalis, differs considerably on the two sides. Thus, of the total length of both hemispheres, this region in the left hemisphere occupies 27 per cent., whereas on the right side it occupies 36 per cent. On both sides the complexity is considerable, but the gyri on the left side are broader superficially than in the right hemisphere, in which the secondary sulci are somewhat deeper and more branched.

The regio occipito-temporalis is thus larger in the right than in the left hemisphere. Its greater development longitudinally has been effected at the expense of (almost entirely) the lower halves of the gyri centrales, and, to a small degree, the lobi occipitales.

The *gyri angulares* are at their upper borders of equal length (the hemispheres are equal in length), but the gyrus in the left hemisphere is bolder, and has a more expanded surface of cortex. The *gyri supramarginales* are nearly symmetrical.

The *gyrus centralis posterior*, though of somewhat different outline, is of equal volume on the two sides, when its connection with the lobulus parietalis superior is included. On both sides its upper two-thirds and the lobulus parietalis superior are simply modelled. The *opercula* are similar, and present no noteworthy points of development.

*Cerebellum*.—The cerebellum is well developed and beautifully symmetrical. The sulci are normal in arrangement. The folia are remarkably fine and narrow, the average breadth not exceeding 1.2 millims. Many are again subdivided on their surface by subordinate grooves.

*The Cranial Nerves*.—The cranial nerves are normal in arrangement and symmetrical.

The *Tuber cinereum* and *Corpora albicantia* are normal and symmetrical.

*Ventricles*.—The lateral and third ventricles, exposed by the removal of the left hemisphere, appear to be normal and proportionately developed.

*Pons Varolii*.—The pons is small (2·5 cm.) in longitudinal depth, but normal in outline and proportion.

*Medulla oblongata*.—The bulb is normal in every particular.

*Summary.*

The brain of Mr. BABBAGE is worthy of record as presenting evidence on :—

(1) The neurological value of symmetry as a feature of cerebral growth in an individual of high intellectual ability.

(2) The relative development of the areas of representation of locutory and graphic functions in contrast to sensorial representation.

APPENDIX I.

*Weights* (preserved in alcohol for 36 years).

L. hemisphere . . . . .	396 grammes.
R. hemisphere and cerebellum . . . . .	508 „
	—
Total weight in 1907 . . . . .	904 „

The whole encephalon with pia mater and arachnoid, after draining off the blood and cerebrospinal fluid, weighed, in 1871, 1406 grammes (SIR THOS. SMITH). To this figure should be added (MARSHALL) about 84 grammes to represent the average loss, as ascertained by BOYD, due to senile wasting between the ages of 40 and 80 years. If this be correct, then the normal maximal weight of Mr. BABBAGE'S brain would be 1490 grammes.

*Measurements.*

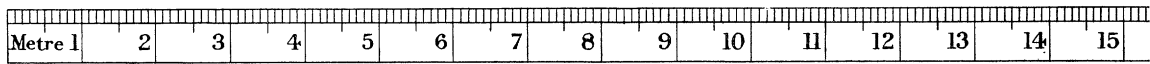
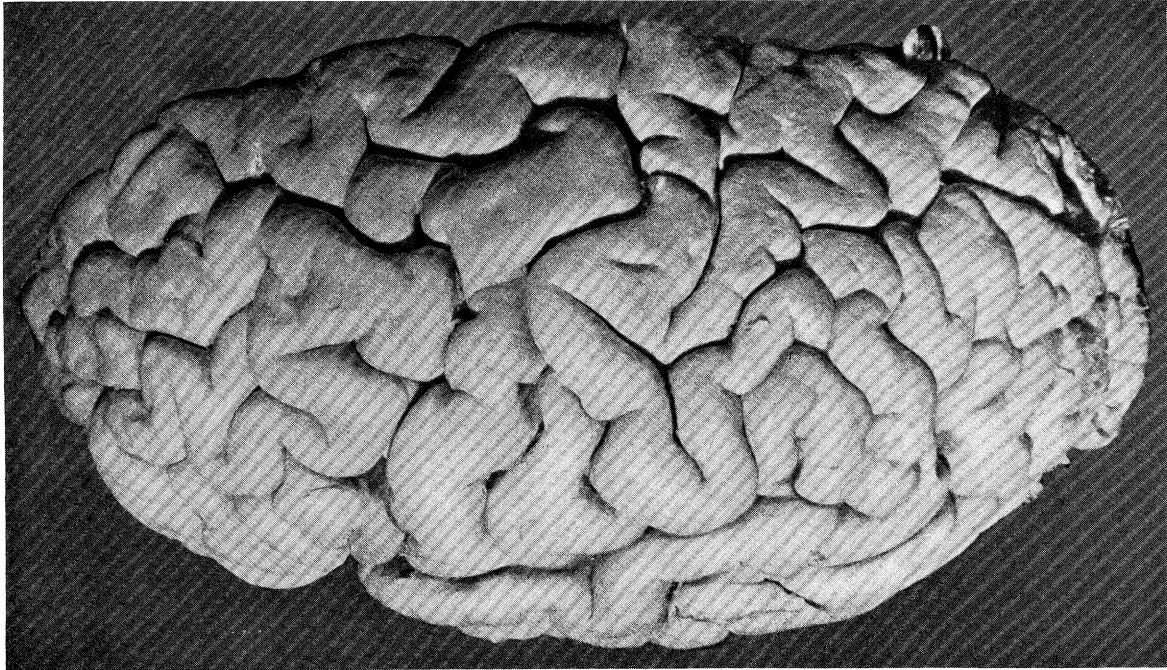	L. hemisphere.	R. hemisphere.
	cm.	cm.
Greatest polar length . . . . .	16·8	16·6
Greatest breadth of orbital surface of frontal lobe . . . . .	5·0	5·3
Greatest thickness of hemisphere, <i>i.e.</i> , from the ganglion interpedunculare to the lower end of the sulcus interparietalis . . . . .	6·4	6·7
Anterior commissure, vertical diameter . . . . .	0·5	—
Anterior commissure, horizontal diameter . . . . .	0·3	—
Middle commissure . . . . .	0·9	—
Pineal body (cystic) . . . . .	0·9	—
Corpus albicans, sagittal diameter . . . . .	0·55	0·4
Crus cerebri, greatest breadth at section . . . . .	1·8	1·8
Corpus callosum, length in mesial plane . . . . .	8·1	—
Anterior colliculus, longitudinal diameter . . . . .	Injured by section of separation	0·9
Anterior colliculus, transverse diameter . . . . .		0·65
Posterior colliculus, longitudinal diameter . . . . .		0·9
(Frænulum, well marked), transverse diameter . . . . .	0·5	0·5
Brachium anterius, transverse diameter . . . . .	—	0·2
Brachium posterius (upper part), transverse diameter . . . . .	—	0·3
Pons, greatest sagittal length, in plane of the pyramid . . . . .	—	2·5
Maximal transverse diameter of bulb at the plane of the pyramidal decussation . . . . .	—	1·3

## LITERATURE.

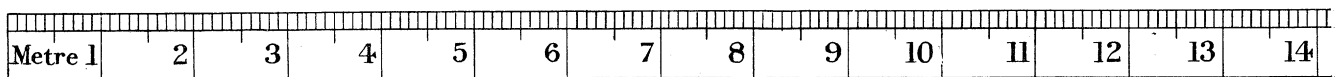
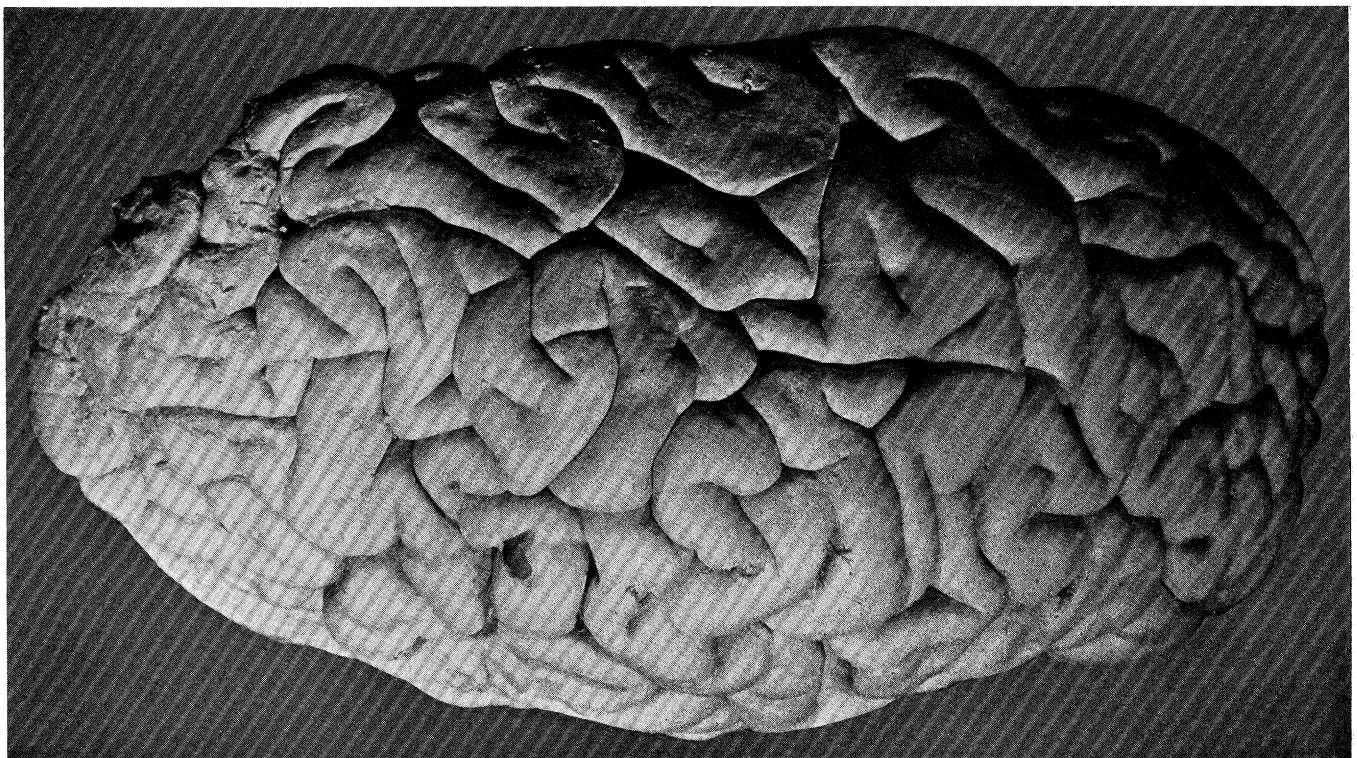
1. CUNNINGHAM. 'Cunningham Memoirs,' No. VII, by Prof. D. J. CUNNINGHAM, M.D., F.R.S. Dublin, Royal Irish Academy, 1892.
2. V. HANSEMANN. "Ueber die Gehirne von TH. MOMMSEN, BUNSEN und AD. v. MENZEL," 'Bibliotheca Medica Schweizerbart,' Stuttgart, 1907.
3. *Idem.* 'Zeitschrift für Psychiatrie,' vol. 20.
4. HORSLEY. Chapter in Prof. CUNNINGHAM'S 'Cunningham Memoirs,' No. VII, 1892.
5. MARSHALL. "The Brain of the Late GEORGE GROTE, F.R.S.," 'Journal of Anatomy and Physiology,' 1893, p. 21.
6. RETZIUS. 'Das Menschenhirn,' 1896. 'Biologische Untersuchungen,' N.F., 1898 to 1905; especially the description of the brain of Prof. CH. LOVÉN, 'B.U.,' Vol. 12, No. 3, 1905.
7. SPITZKA, E. A. "A Preliminary Communication of a Study of the Brains of Two Distinguished Physicians, Father and Son," 'Philadelphia Medical Journal,' April 6, 1901.
8. *Idem.* 'American Anthropologist,' vol. 6, 1904.
9. WAGNER. 'Windungen der Hemisphären und das Gehirngewicht,' Göttingen, 1860.
10. WALDSCHMIDT. 'Allgemeine Zeitschrift für Psychiatrie,' vol. 43, 1887, p. 373.

[*Note.*—After the work described in this paper had been completed, the report by Professor E. A. SPITZKA, entitled "A Study of the Brains of Six Eminent Scientists and Scholars belonging to the American Anthropometric Society, together with a Description of the Skull of Professor E. D. COPE" ('Transactions of the American Philosophical Society, Philadelphia,' 1907, p. 175), came into my hands. I regret that the special points detailed by Dr. SPITZKA, particularly the relative size of the corpus callosum, have not received the attention they deserve.]

LEFT HEMISPHERE.

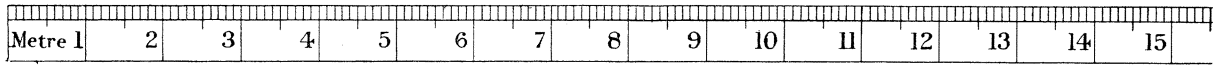
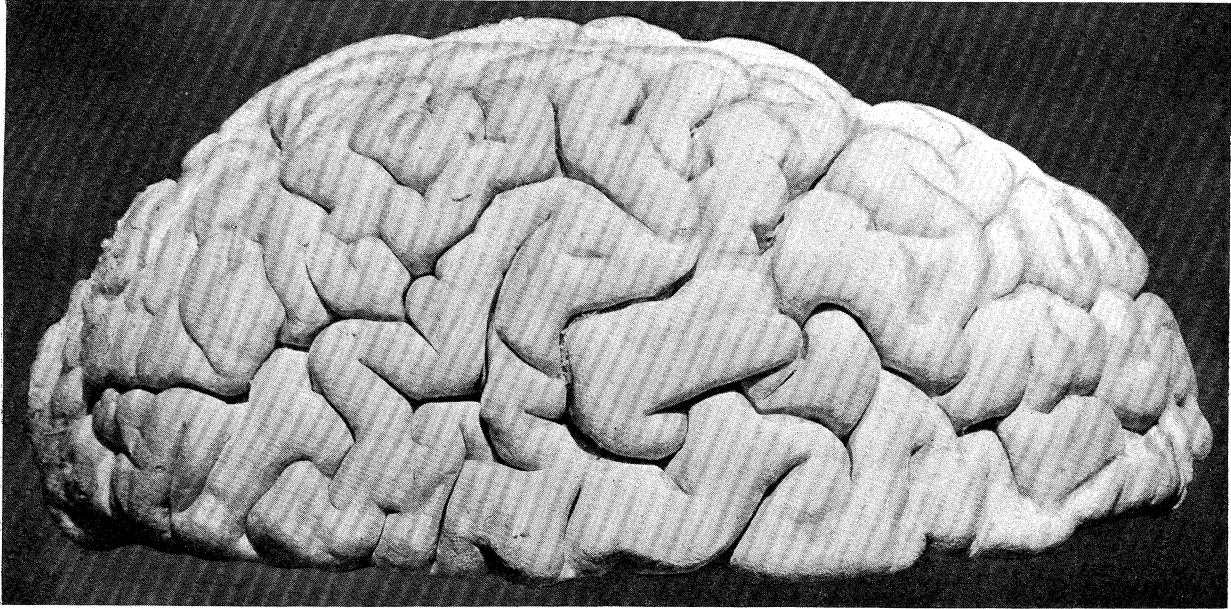


RIGHT HEMISPHERE.

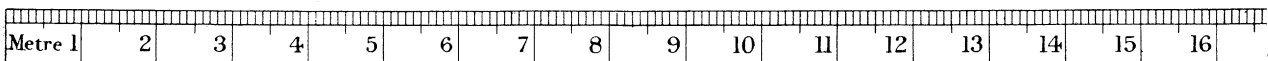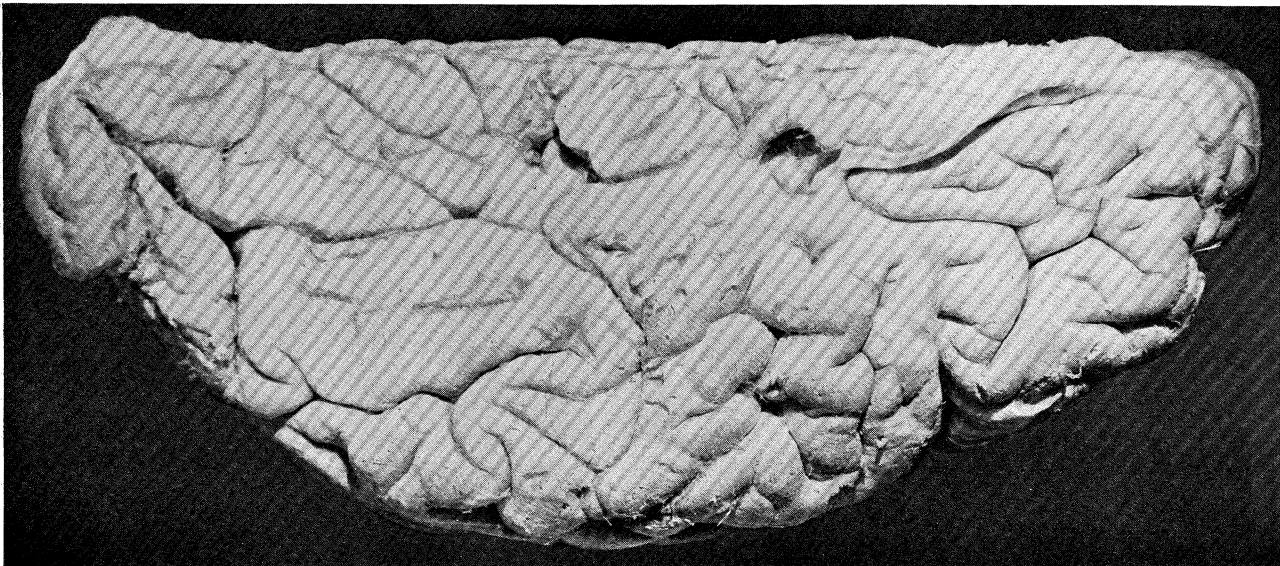




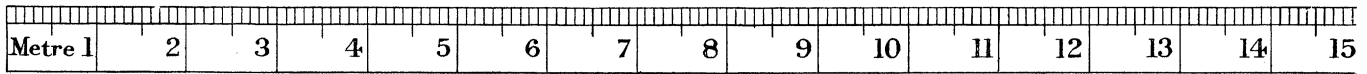
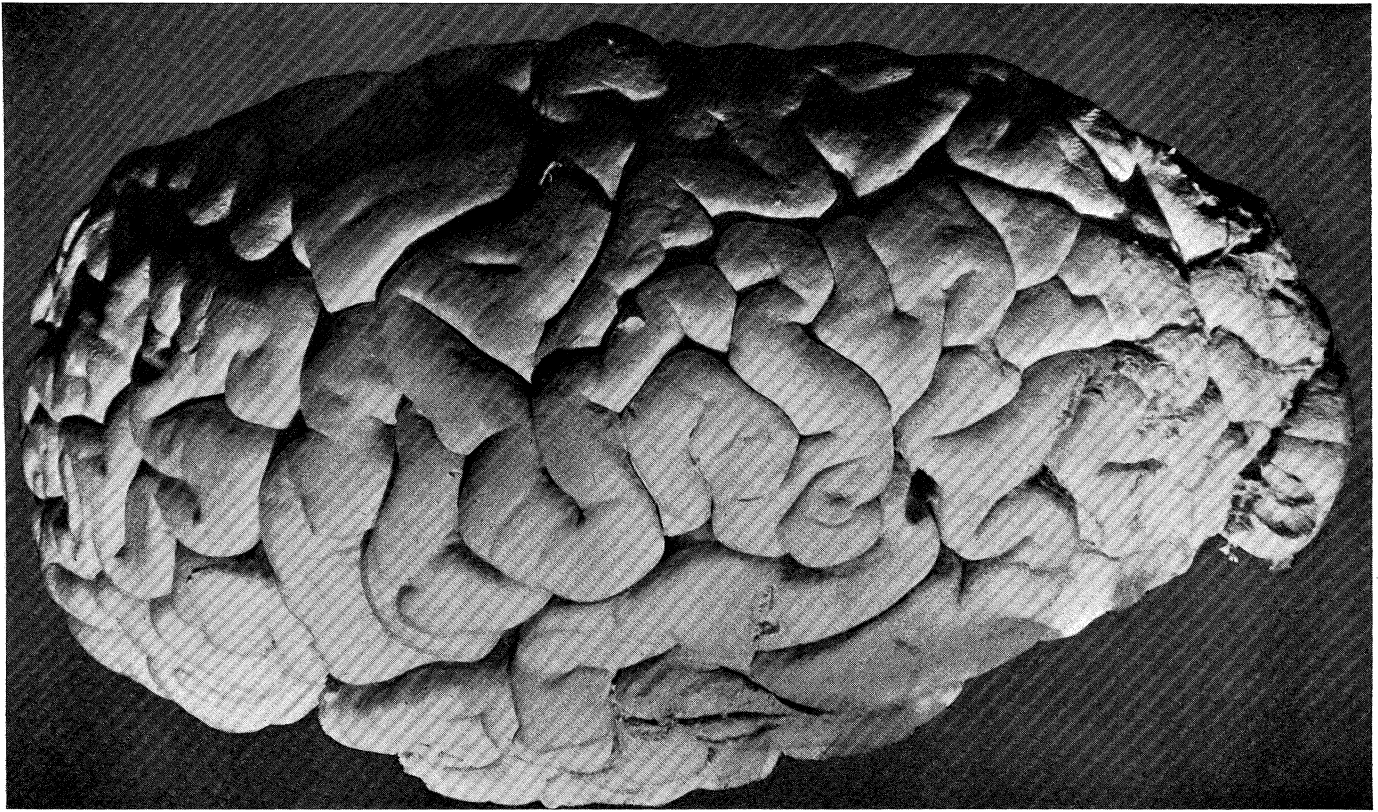
LEFT HEMISPHERE.



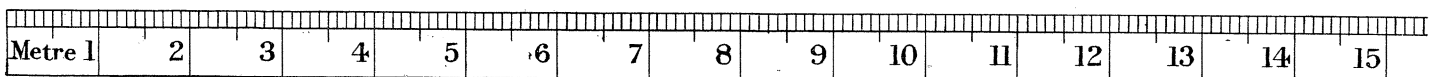
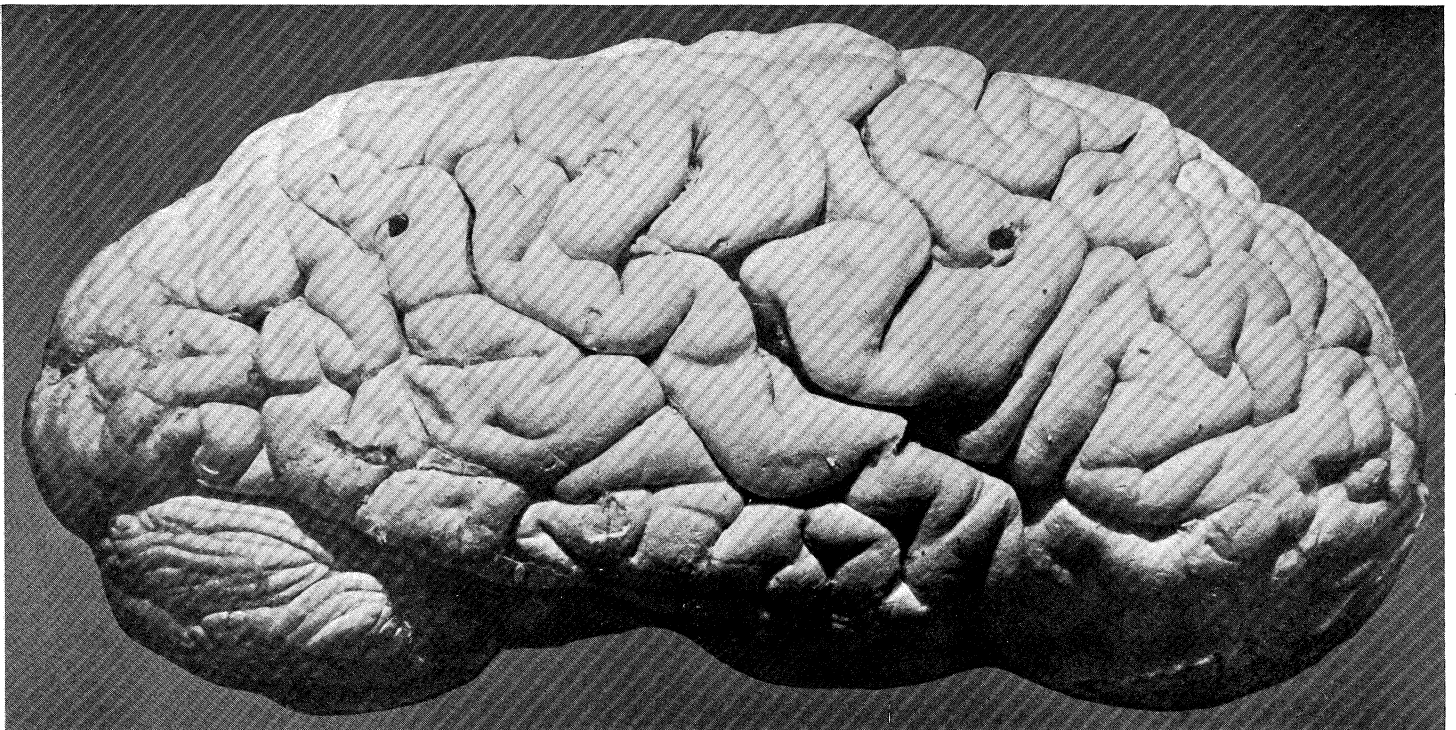
LEFT HEMISPHERE



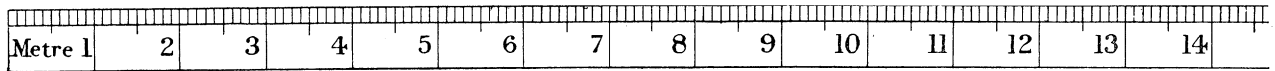
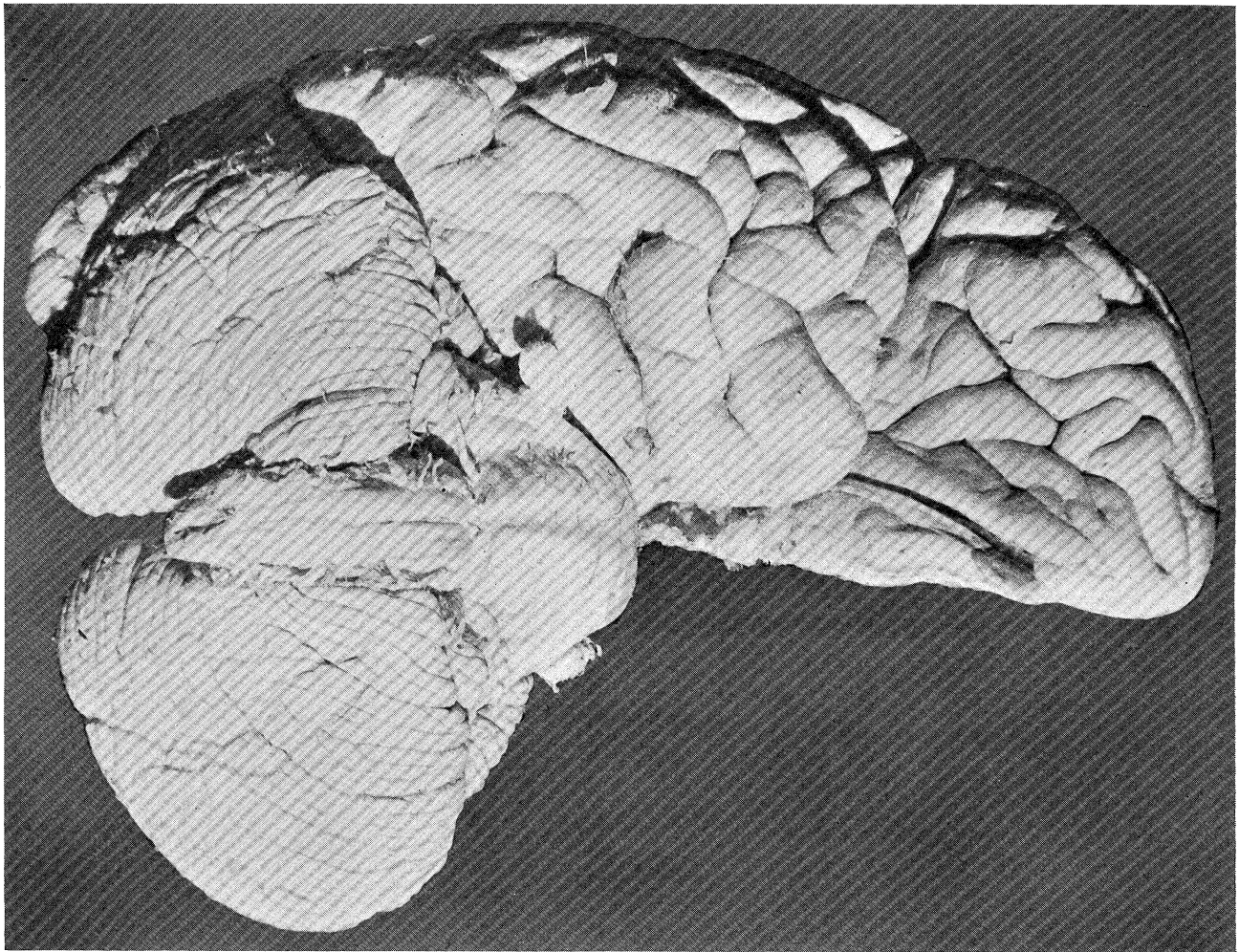
LEFT HEMISPHERE.



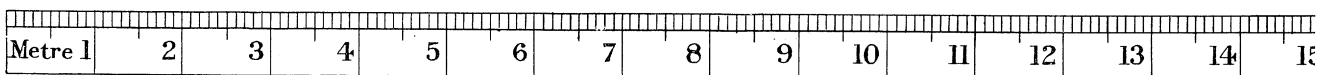
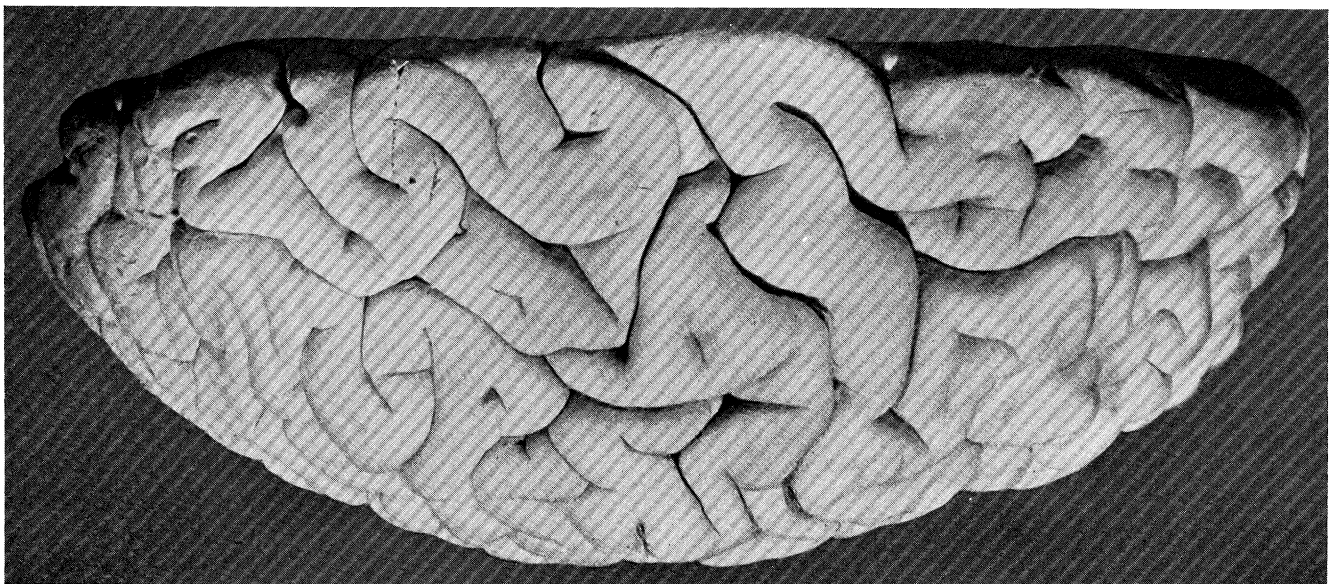
RIGHT HEMISPHERE.



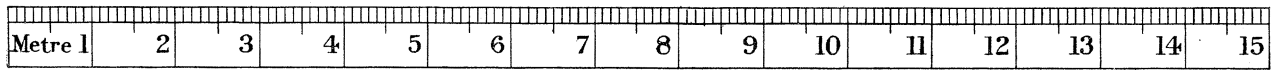
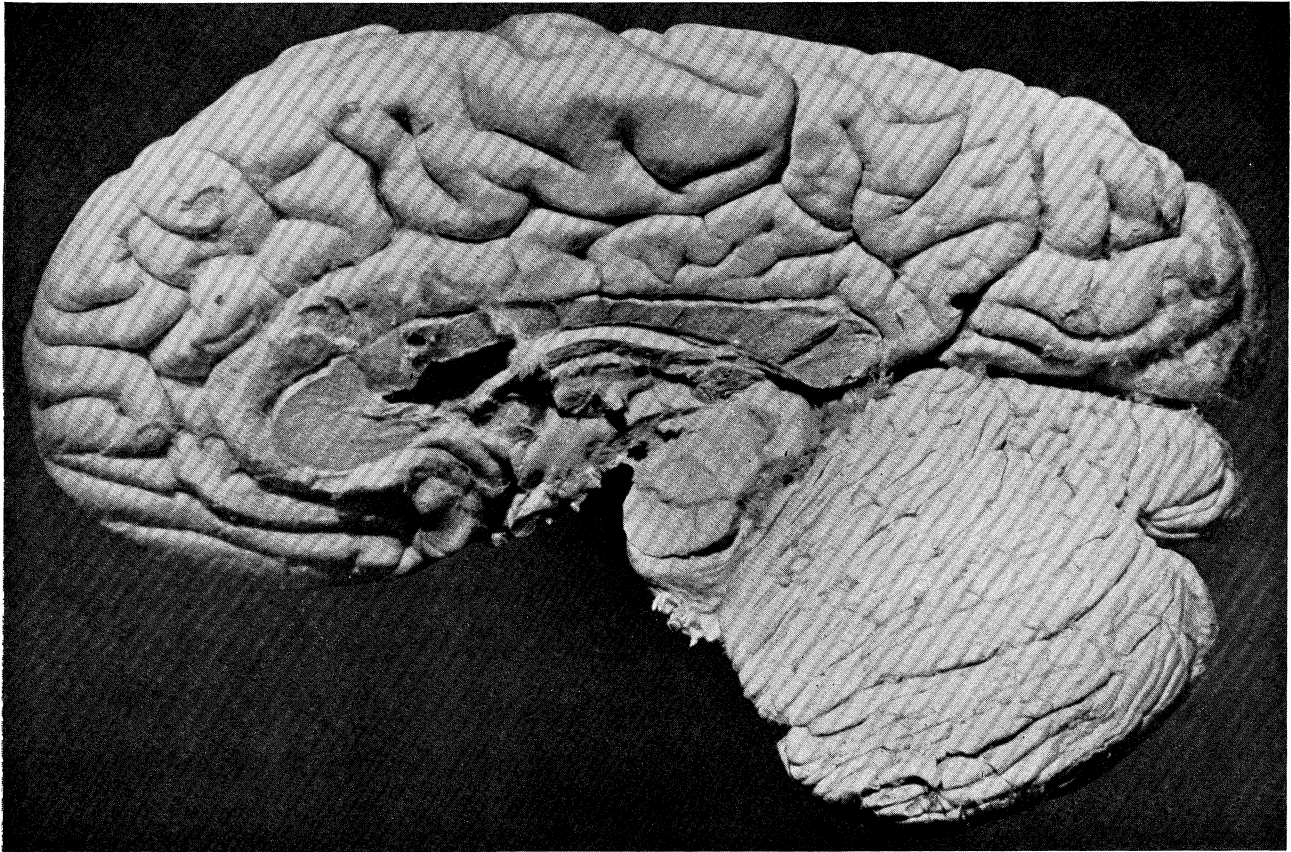
RIGHT HEMISPHERE.



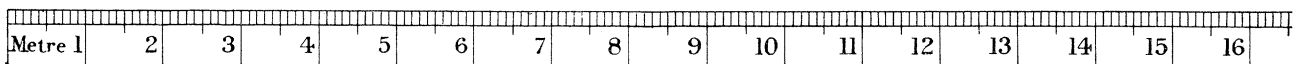
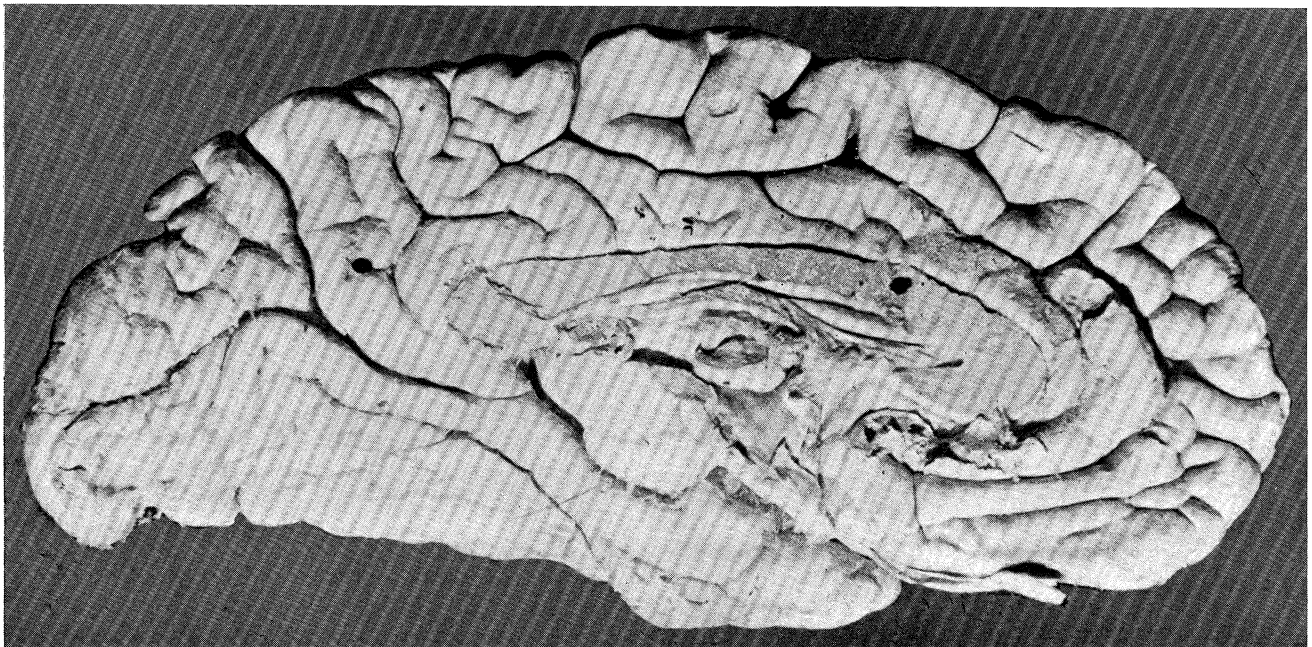
RIGHT HEMISPHERE.




RIGHT HEMISPHERE.

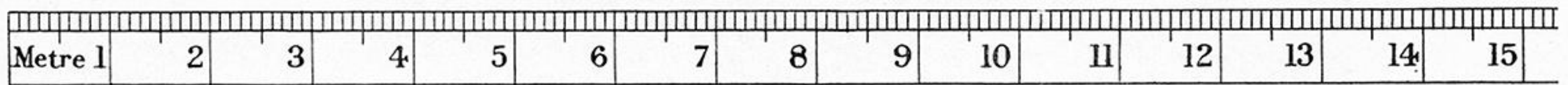
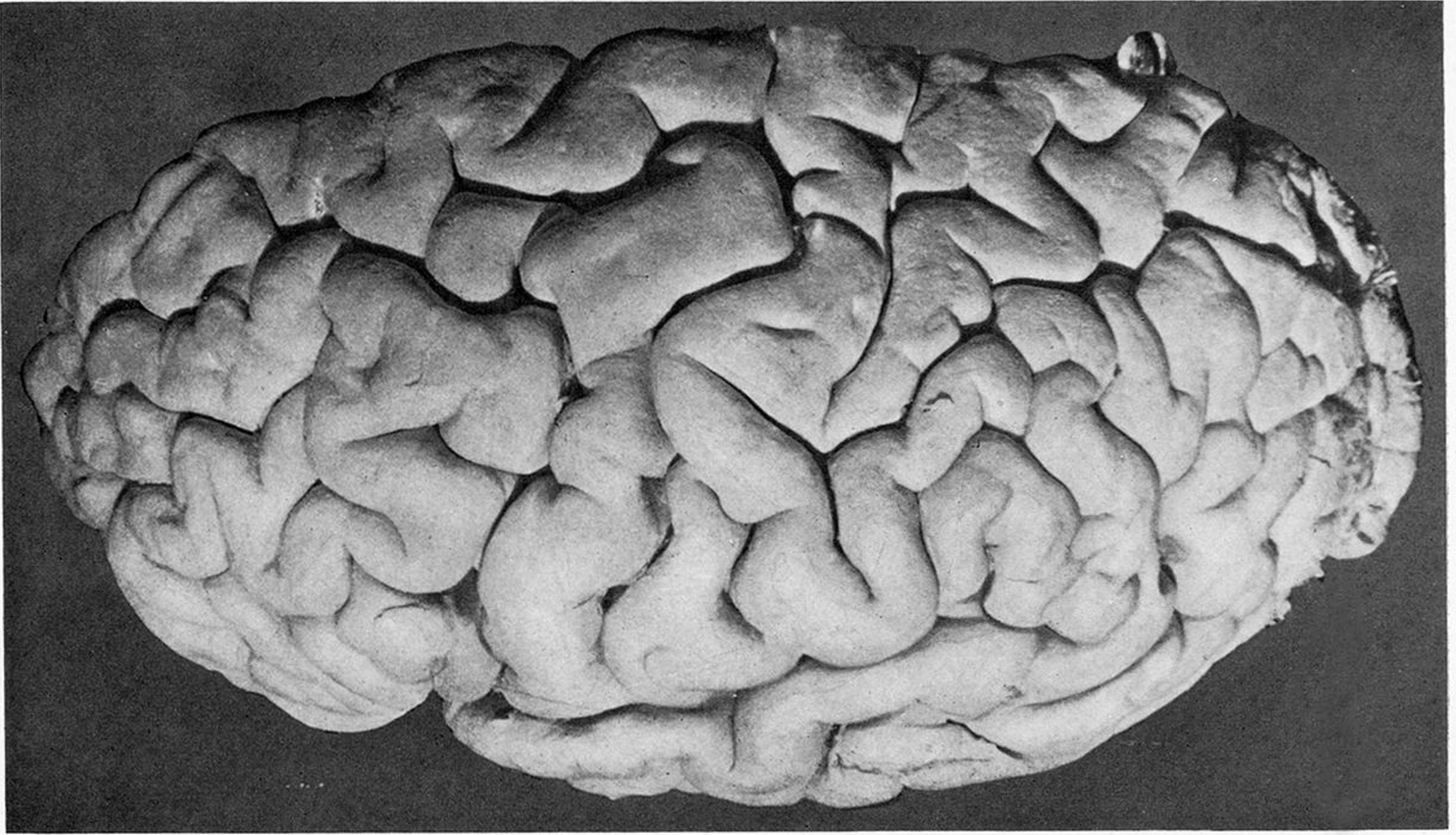


LEFT HEMISPHERE.

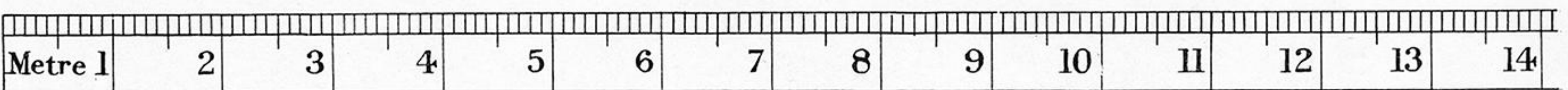
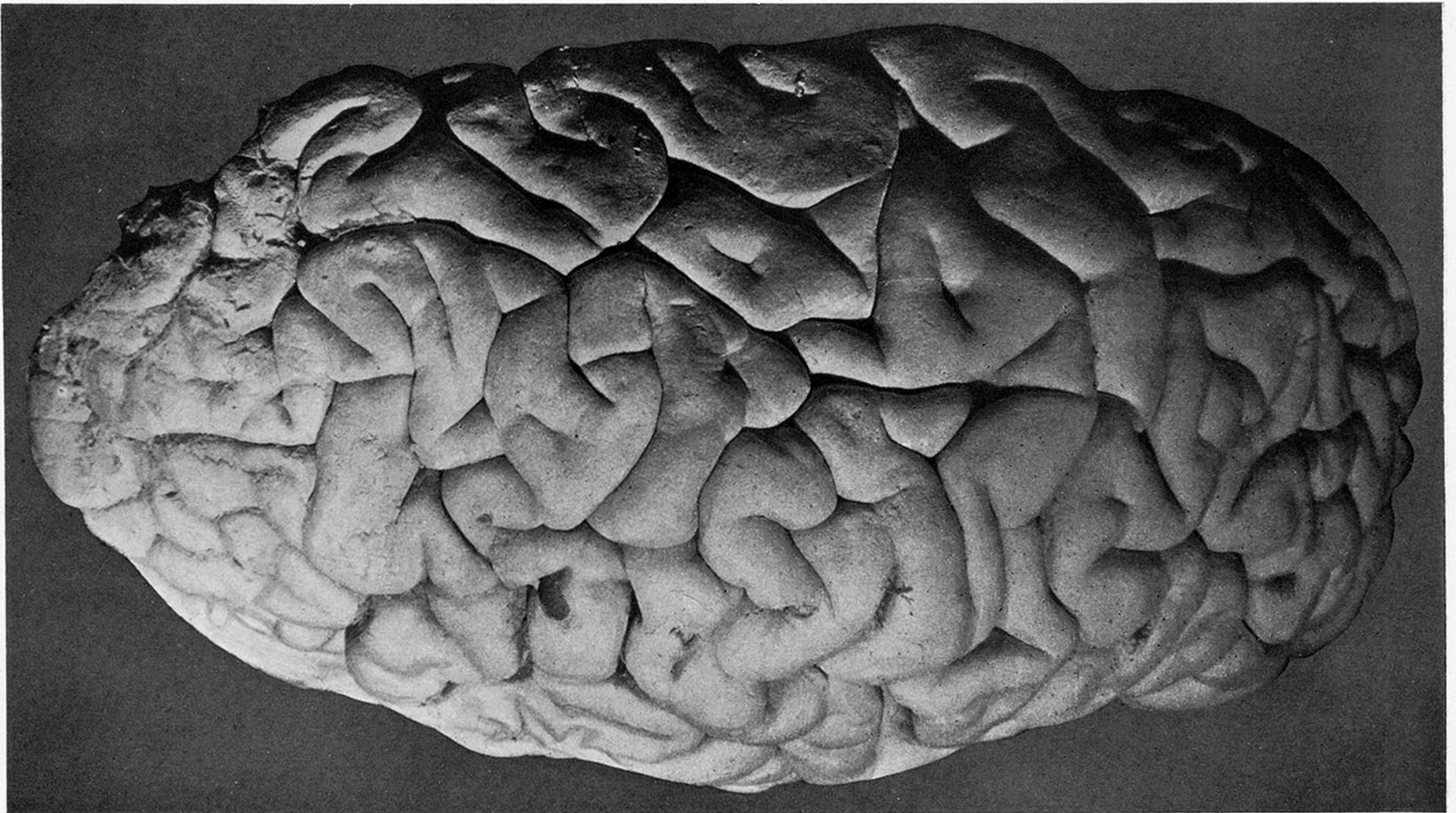




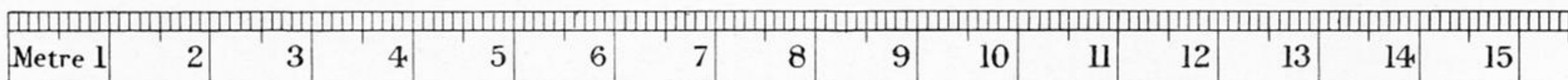
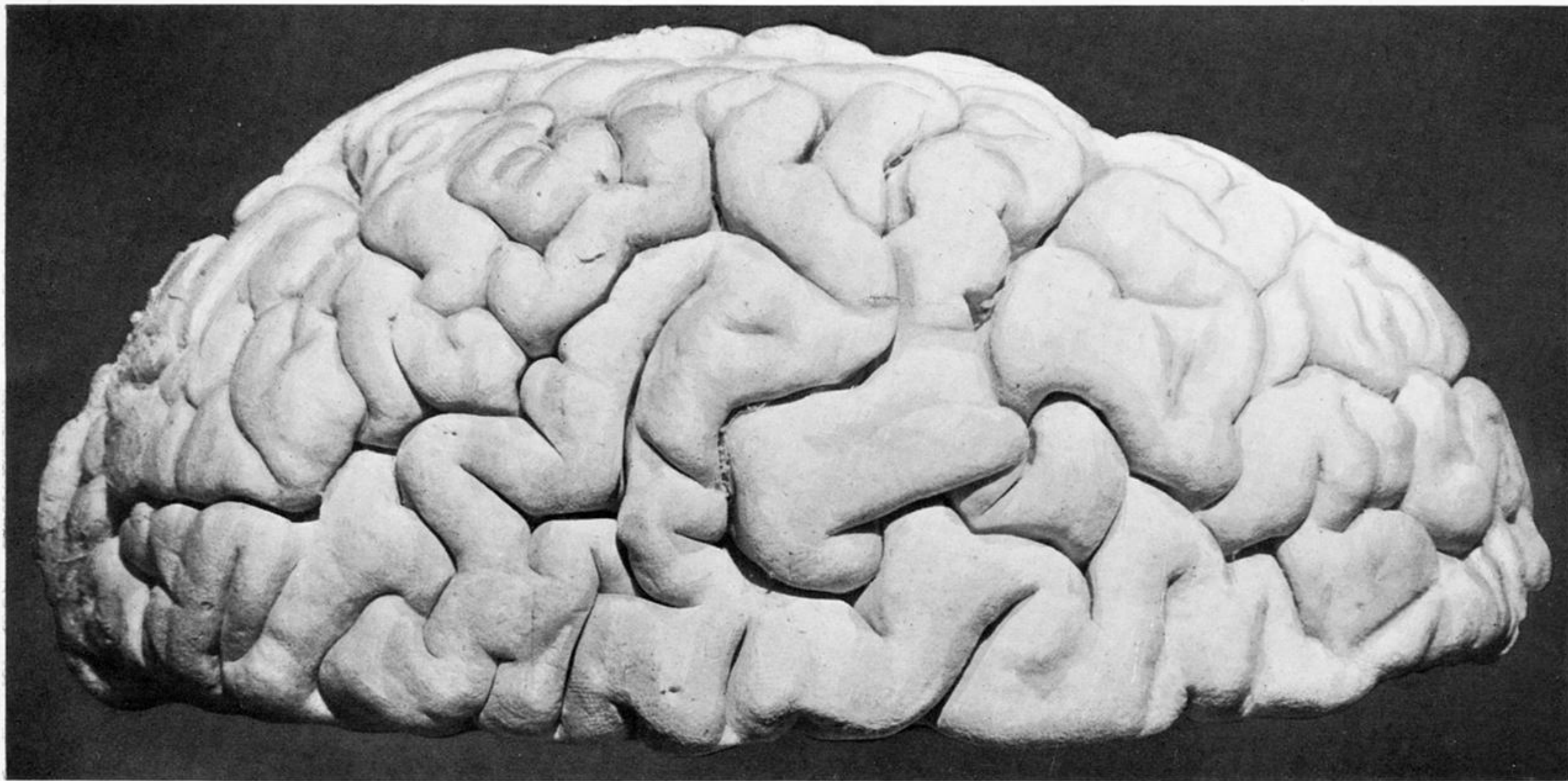
LEFT HEMISPHERE.



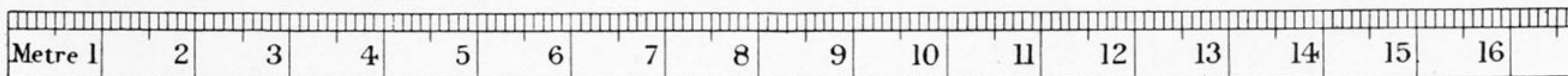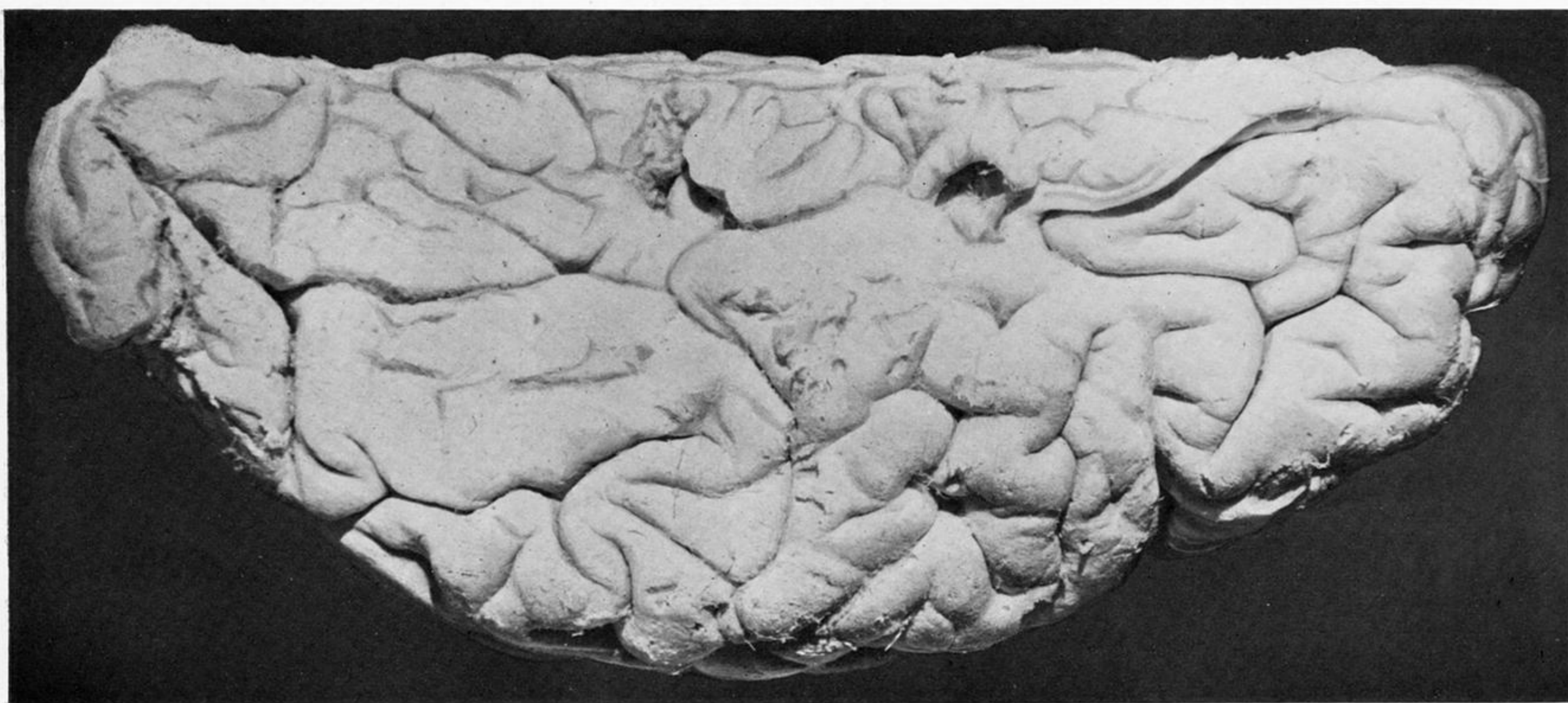
RIGHT HEMISPHERE.



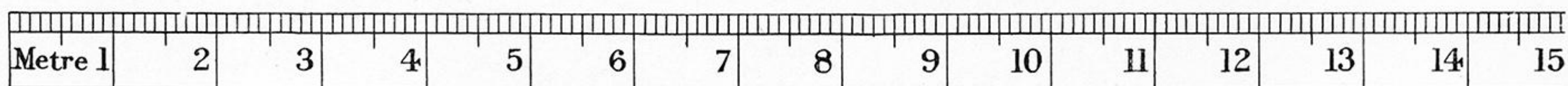
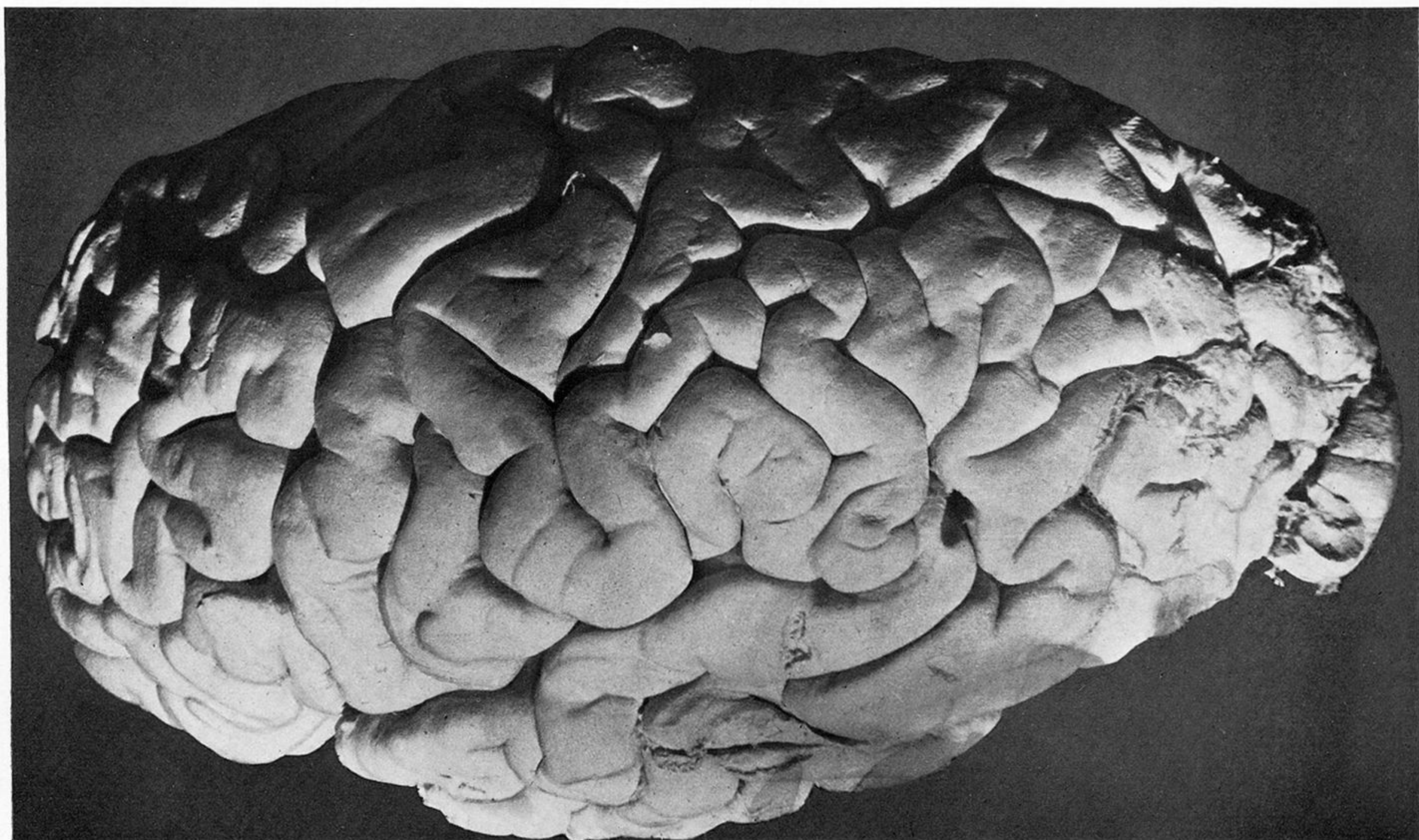
LEFT HEMISPHERE.



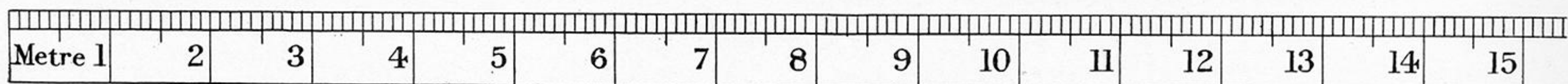
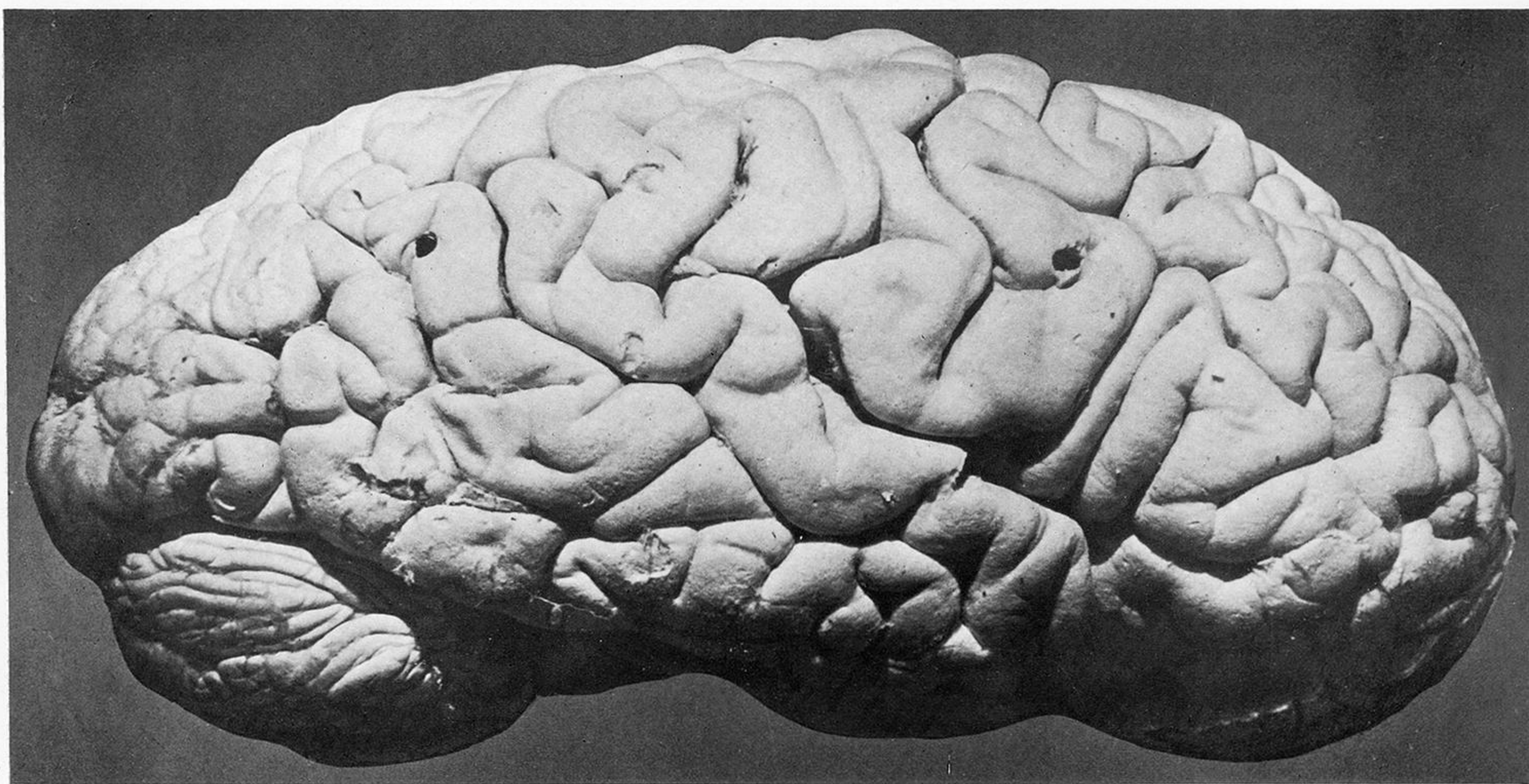
LEFT HEMISPHERE



LEFT HEMISPHERE.

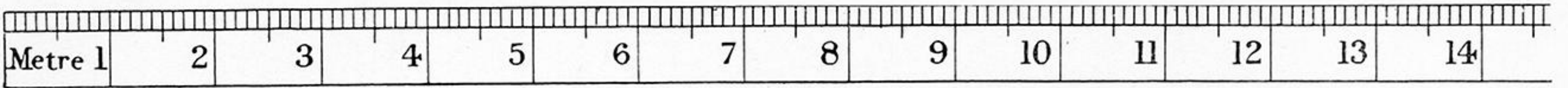
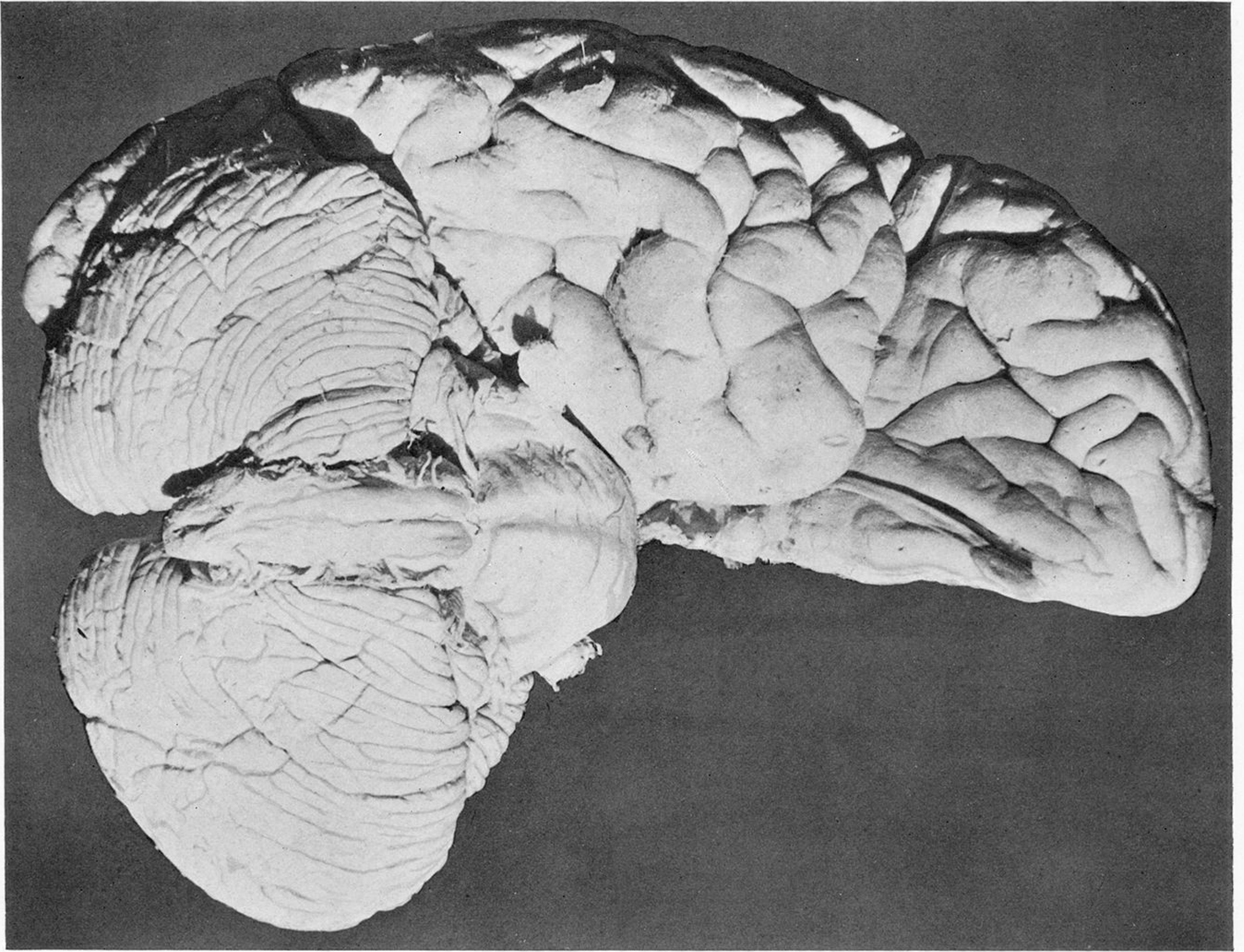


RIGHT HEMISPHERE.

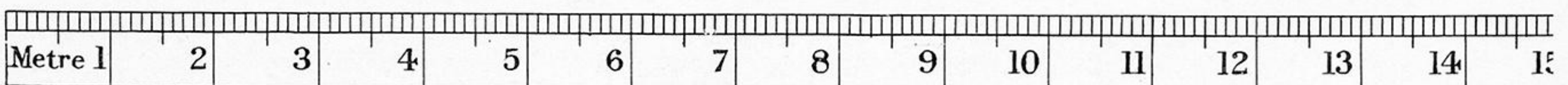
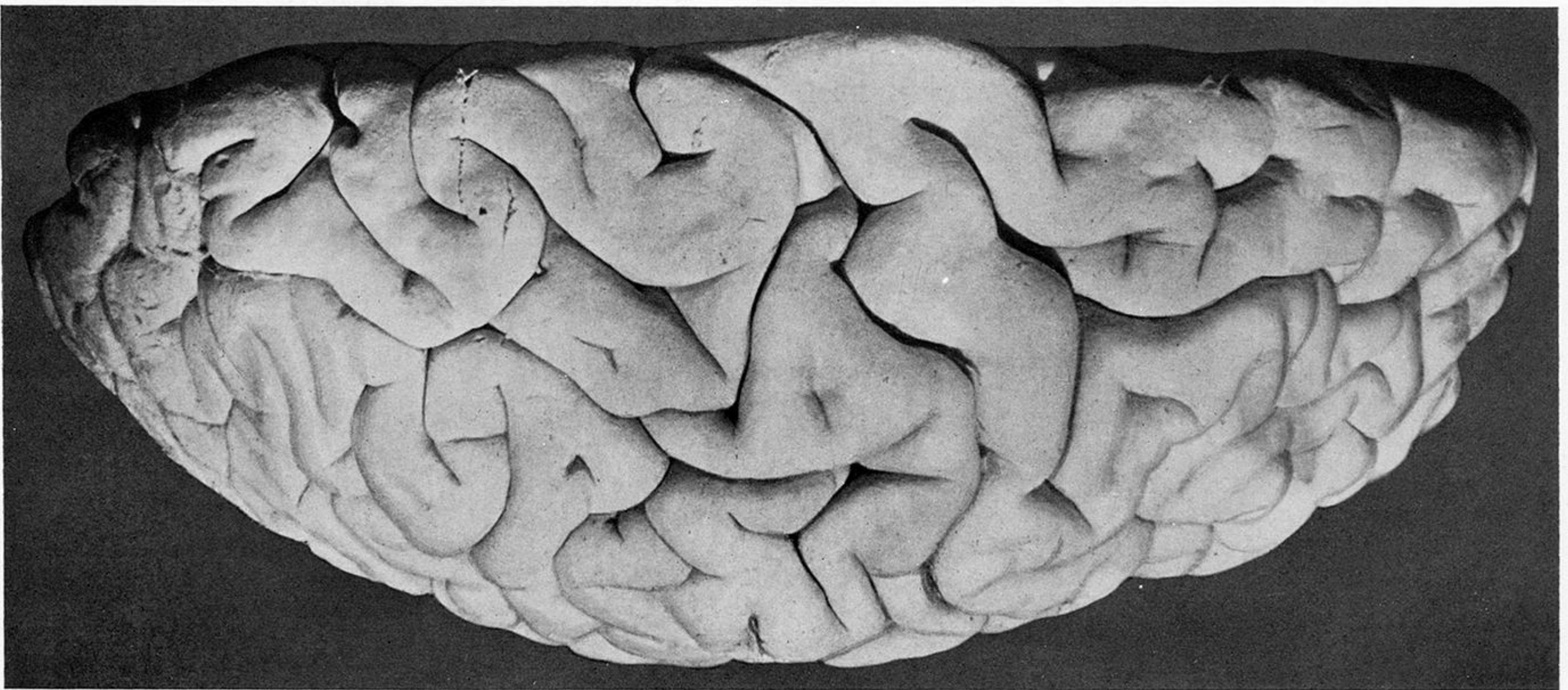




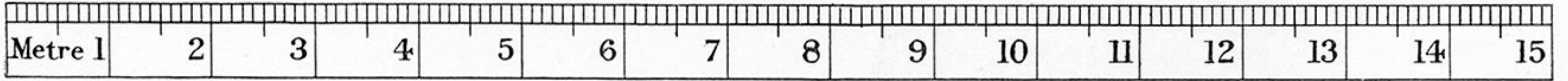
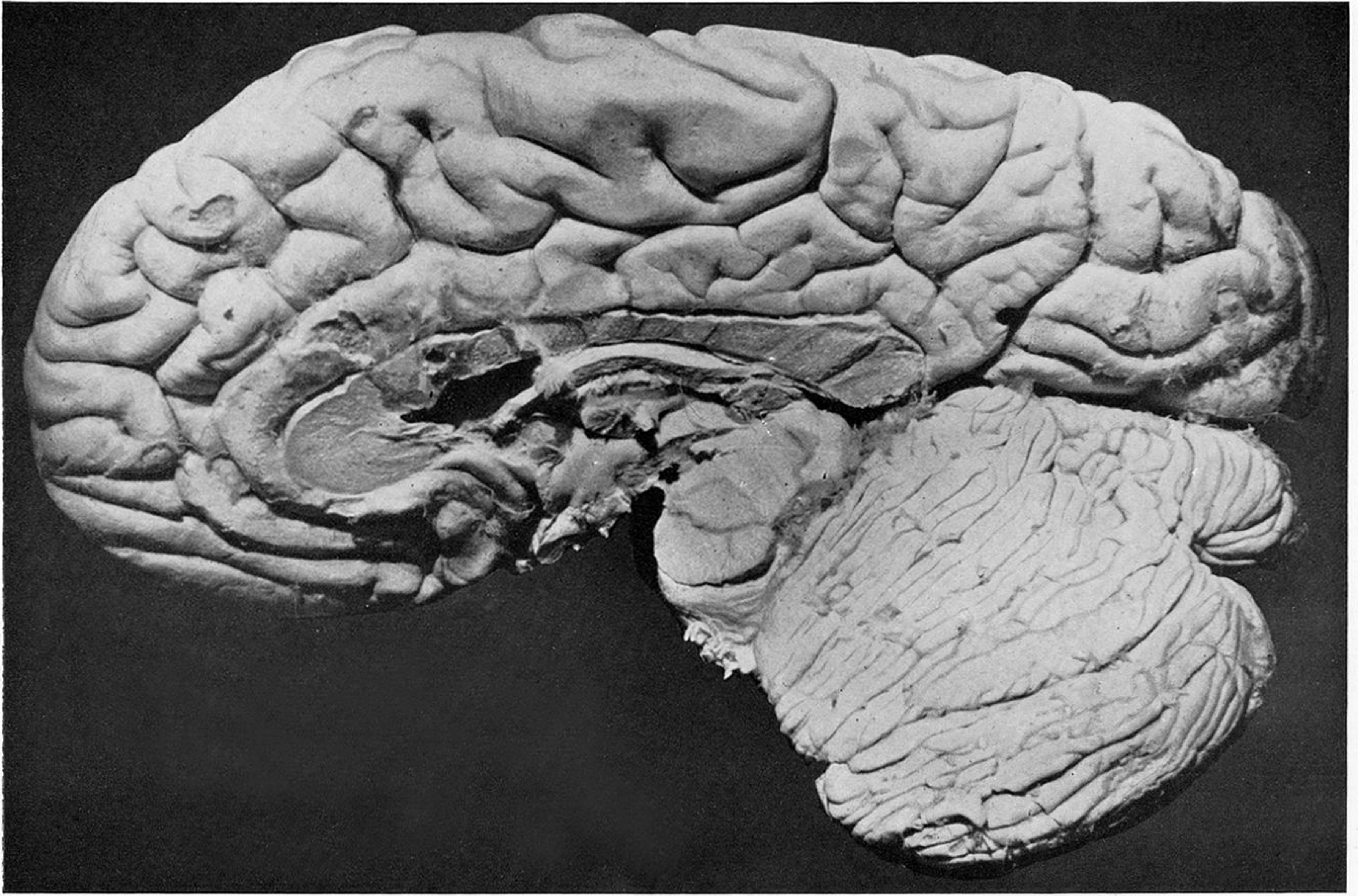
RIGHT HEMISPHERE.



RIGHT HEMISPHERE.



RIGHT HEMISPHERE.



LEFT HEMISPHERE.

